

**SPECIAL COMMUNICATION**

# Tendon Transfer Surgery for People With Tetraplegia: An Overview



Jennifer A. Dunn, PhD,<sup>a,b</sup> K. Anne Sinnott, MPhty,<sup>a,c</sup> Alastair G. Rothwell, MD,<sup>a</sup>  
Khalid D. Mohammed, MD,<sup>a</sup> Jeremy W. Simcock, MD<sup>d</sup>

From the <sup>a</sup>Department of Orthopaedic Surgery and Musculoskeletal Medicine, University of Otago, Christchurch; <sup>b</sup>Burwood Spinal Unit, Burwood Hospital, Christchurch; <sup>c</sup>Burwood Academy of Independent Living, Burwood Hospital, Christchurch; and <sup>d</sup>Department of Surgery, University of Otago, Christchurch, New Zealand.

## Abstract

After cervical spinal cord injury, the loss of upper limb function is common. This affects an individual's ability to perform activities of daily living and participate in previous life roles. There are surgical procedures that can restore some of the upper limb function lost after cervical spinal cord injury. Tendon transfer surgery has been performed in the tetraplegic population since the early 1970s. The goals of surgery are to provide a person with tetraplegia with active elbow extension, wrist extension (if absent), and sufficient pinch and/or grip strength to perform activities of daily living without the need for adaptive equipment or orthoses. These procedures are suitable for a specific group, usually with spinal cord impairment of C4-8, with explicit components of motor and sensory loss. Comprehensive team assessments of current functioning, environment, and personal circumstances are important to ensure success of any procedure. Rehabilitation after tendon transfer surgery involves immobilization for tendon healing followed by specific, targeted therapy based on motor learning and goal-orientated training. Outcomes of tendon transfer surgery are not limited to the improvements in an individual's strength, function, and performance of activities but have much greater life affects, especially with regard to well-being, employment, and participation. This article will provide an overview of the aims of surgery, preoperative assessment, common procedures, postoperative rehabilitation strategies, and outcomes based on clinical experience and international published literature.

Archives of Physical Medicine and Rehabilitation 2016;97(6 Suppl 2):S75-80

© 2016 by the American Congress of Rehabilitation Medicine

After cervical spinal cord injury (SCI), impairments to the upper limb are common for both complete and incomplete injuries. For individuals with an injury to C5-8, shoulder muscles often retain strength, but the muscles controlling the elbow, wrist, forearm, and hand have weak or no active movement, depending on the level of injury. This affects the individual's ability to perform functional activities and to participate in previous life roles. Return of arm and hand function has been reported as the highest priority for people with tetraplegia—above walking, bowel, bladder, and sexual function.<sup>1,2</sup> Traditionally, nonsurgical rehabilitation of the upper limb for people with tetraplegia has consisted of strengthening innervated muscles followed by learning compensatory techniques, provision of orthotics, or environment modification to facilitate function.<sup>3</sup> However, orthotic devices have poor long-term acceptance by people with tetraplegia,<sup>4,5</sup> and environment modification outside the individual's home

environment is limited or absent. Tendon transfer surgery is one method of restoring upper limb function with the aims of reducing the need for orthotics and adaptive equipment and increasing function.

Surgical reconstruction of the upper extremity, using tendon transfers, in people with tetraplegia was first popularized by Moberg in the 1970s. Since that time, the procedures have remained true to this principle and have been adopted by many centers worldwide.<sup>6-13</sup> His guiding principle was that the outcome of any reconstructive procedures was dependent on wrist extension torque and the availability of active muscles for transfers,<sup>14</sup> as determined by the International Classification for Surgery of the Hand in Tetraplegia.<sup>10</sup> Voluntary active wrist extension is the key to good grasp in people with tetraplegia, with or without tendon transfer surgery, because of the tenodesis action initiated by the wrist. This tenodesis occurs because the tendons of the finger and thumb pass over the wrist; therefore, when the wrist is actively extended, passive tension of the flexor muscles puts them under tension, creating a gross grip pattern of the fingers and a lateral

pinch of the thumb (fig 1). Conversely, finger and thumb openings can be created by flexing the wrist to increase the passive force in the tendons of the extensor muscles.<sup>15,16</sup> However, these forces are weak (1–2N maximum) and dependent on the posture of the fingers and thumb.<sup>16</sup> Most activities of daily living (ADL) performed by people with tetraplegia (eg, opening and closing a zip, pressing a remote control button, stabbing food with a fork) require pinch forces  $>2N$ .<sup>17</sup>

Common tendon transfer procedures include provision of elbow extension (if absent) by posterior deltoid to triceps or biceps to triceps transfer, provision of wrist extension (if absent), and creation of pinch and/or finger-palm grasp. Innovative techniques (eg, implanted functional electrical stimulation,<sup>18</sup> nerve transfers<sup>19–22</sup>) have more recently been used in conjunction with tendon transfers to optimize arm and hand function in people with tetraplegia.

## Timing for surgery

It has been established that the greatest proportion of motor and sensory recovery will occur within the first 6 to 9 months after SCI.<sup>23,24</sup> People with tetraplegia are not usually considered for tendon transfer surgery until after this time to ensure that they have reached their plateau of neurologic recovery.<sup>18,25,26</sup> There is, however, no contraindication to those who wish to have surgery many years after their injury.<sup>6</sup> It is important that the individual has reached their functional potential and demonstrated psychological adjustment to their SCI and motivation to improve their physical functioning prior to referral for surgery.<sup>27</sup> In addition, as with many surgical procedures, the outcomes of surgery are reliant on the preoperative condition of the limb. For tendon transfer procedures to be effective, it is important that the upper limb demonstrate normative, pain-free passive range of motion in all of the joints.

## Principles of surgery

Tendon transfer procedures involve surgical transfer of the distal tendon from an innervated muscle into the tendon of a paralyzed muscle to restore movement. The proximal attachment of the donor muscle is left intact and may continue to perform its original function. When the donor muscle is voluntarily activated, movement across each joint of its new anatomic location is possible.

Essentially, tendon transfer surgery is suitable for people who have sufficient strength in their proximal upper limb to lift their hand to their mouth. This is generally those with C5–8 SCI. Individuals at these levels lack active elbow extension (C5–6), wrist extension (C5), finger and thumb flexion (C5–7), finger and thumb extension (C–6), and thumb opposition (C8). Although not all of the complex movements of the nonimpaired hand can be recreated, basic pinch and grip are possible and can significantly

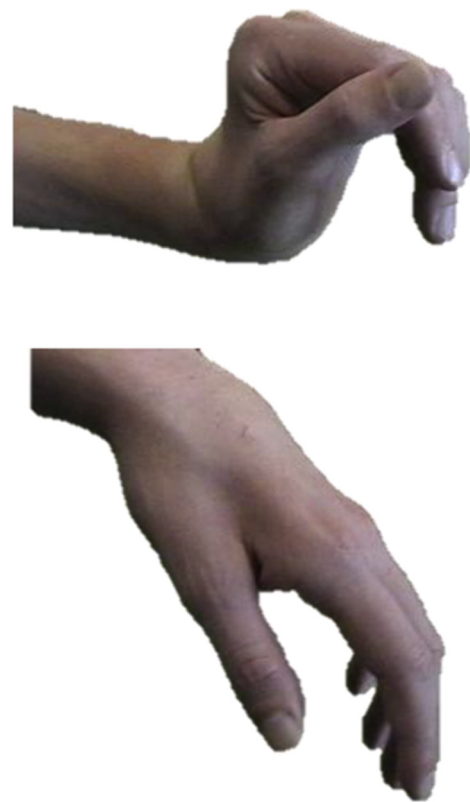

Fig 1 Passive tenodesis.

improve functional performance. Surgical reconstruction of hand function has been a specialized area of expertise dominated by the knowledge of surgical techniques and advanced through biomechanical research. The muscle selected for the transfer (the donor muscle) is dependent on a number of factors, including strength, route and direction of the transfer, architecture of the donor muscle and the function required, and synergism of the tendon transfer. Optimally, the donor muscle should be Medical Research Council grade 4 or 5 because it is expected to lose a grade of strength performing its new action after transfer. Transfer of a weak donor muscle will not be effective in performing its new role. The surgical technique is specific for each donor muscle and is based on knowledge of its force-producing capacity. Post-operative muscle reeducation may be easier if the muscle's original and new functions are synergistic. For example, wrist extension and hand closing occur together naturally. Therefore, learning to close the hand after transfer of a wrist extensor to the finger flexors may facilitate activation postoperatively. It is critical to ensure that the potential donor muscle for transfer has redundant function and its synergists are strong so it will not reduce the individual's current level of functioning.

The level of SCI generally determines the muscles and options available for transfer. Strong grasp or pinch requires active contraction of the intrinsic and extrinsic hand musculature. Depending on the available muscles for transfer, these functions may be restored actively or passively.<sup>28</sup> Wrist extension is fundamental to the success of other transfers and if there is only 1 available donor muscle, it will be used to restore wrist extension. With active wrist extension, the passive tension in the finger flexors and extensors can be used to open and close the hand, as

### List of abbreviations:

ADL	activities of daily living
ICF	International Classification of Functioning, Disability and Health
ISNCSCI	International Standards for Neurological Classification of Spinal Cord Injury
SCI	spinal cord injury

previously described. This effect can also be enhanced to provide greater passive force, by anchoring selected tendons to the bone in a shortened range (tenodesis). With additional donor muscles and an already strong wrist extensor, active pinch and grip can be restored with transfers to the thumb and finger flexors.

In the absence of an available active muscle for transfer, tenodesis and arthrodesis may be used to provide other functions of the hand as long as there is sufficient wrist extensor torque to power them.<sup>29-31</sup> These procedures limit the degrees of freedom that must be controlled by only a few muscles. Arthrodesis (fusing a joint) is particularly useful in stabilizing the thumb at the carpometacarpal or metacarpophalangeal joint to provide effective positioning and control to produce pinch function. This may however limit thumb opening and acquisition of larger objects. The strength of tenodeses to provide key pinch is approximately half the strength provided by active transfers.<sup>32</sup> Precision versatility and utility of pinch is better in active transfers than tenodesis.<sup>11,25,33,34</sup>

### Preoperative assessment

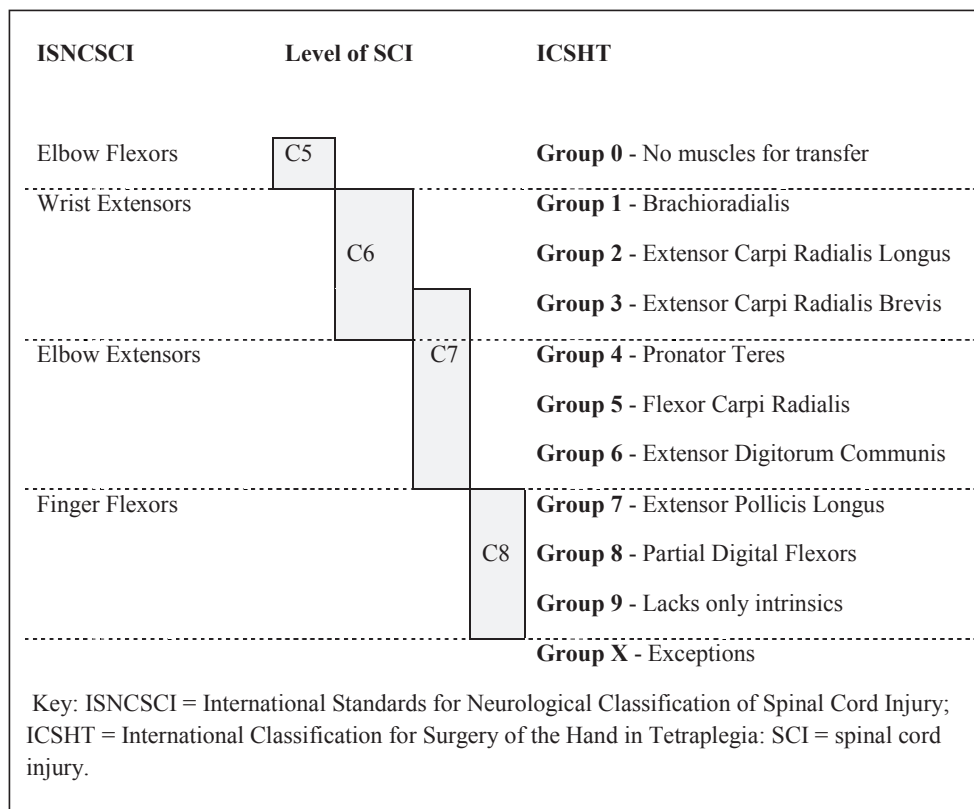
It is important that assessment for tendon transfer surgery is performed by a team including physiatrists, surgeons, and therapists. This ensures a comprehensive assessment of strength, sensation, upper limb, and global function is obtained and provides a baseline for the evaluation of the procedures over time. This will also facilitate goal setting for the surgical procedures.

One important component of selecting the appropriate surgical procedures is the evaluation of strength and sensation of the upper limb. Although the International Standards for Neurological

Classification of Spinal Cord Injury (ISNCSCI)<sup>35</sup> provide a common understanding of the degree of impairment after SCI, it is not particularly useful for assessing the potential for tendon transfer surgery. One of the limitations of the ISNCSCI is that it provides insufficient information on all upper limb muscles and sensation, particularly in the hand.<sup>36</sup> In addition, the ISNCSCI is not sensitive enough to detect small but clinically significant changes in arm and hand strength. Therefore, a more specific classification, the International Classification for Surgery of the Hand in Tetraplegia has been developed specifically for assessment of surgical planning in the upper limb (fig 2).<sup>10</sup> In addition, therapists need to implement assessment of an individual's function over the 3 domains of the *International Classification of Functioning, Disability and Health (ICF)*,<sup>37</sup> using validated outcome measures for this population.<sup>3,36,38-40</sup> More importantly, the person with tetraplegia needs to be involved in the decision-making process for surgery to ensure procedures are individualized to that person.<sup>27</sup> This ensures that the type of surgically created grasp will best meet the goals of the individual and may result in different surgical procedures being performed on each arm/hand.

### Surgical procedures

The number and type of procedures that can be performed are based on the individual's International Classification for Surgery of the Hand in Tetraplegia. Individuals with a greater number of muscles available for transfer will have more options for reconstructing specific hand functions.



**Fig 2** Comparison of ISNCSCI and International Classification for Surgery of the Hand in Tetraplegia key muscles.

## Summary of common procedures

Surgeons have personal preferences for using different surgical procedures based on experience and prior outcomes. Surgical literature should be reviewed for the details of specific procedures because they are constantly under revision to improve techniques for achieving the optimal outcome. There are a number of common procedures with predictable outcomes that restore basic upper limb functions in this population.<sup>6,26,28,34,41-44</sup>

For the provision of active elbow extension either a biceps brachii to triceps brachii<sup>45,46</sup> or a deltoid to triceps brachii<sup>26,47,48</sup> transfer can be offered. Both procedures have an immobilization period/reeducation period of up to 8 weeks after surgery before any functional rehabilitation can commence. For the provision of wrist extension, pinch and/or grip surgical options for tendon transfer are dependent on the number of spare active muscles available and the individual's goals. The brachioradialis is the most commonly available muscle for transfer because it is considered a spare elbow flexor because the biceps is the primary elbow flexor. Therefore, the brachioradialis can be used for a transfer into either wrist or finger extensors or thumb or finger flexors. Other muscles available for transfer, depending on the level of SCI, include extensor carpi radialis longus, pronator teres, flexor carpi radialis, and palmaris longus. Palmaris longus, extensor digiti minimi, and flexor digitorum superficialis may also be used as passive transfers for tenodeses. The split distal flexor pollicis longus tenodesis described by Mohammed et al<sup>6</sup> is an alternative to thumb interphalangeal joint arthrodesis for the prevention of excessive flexion of the thumb during pinch. Common surgical procedures are shown in table 1.

## Principles of rehabilitation after tendon transfer surgery

During the immediate postoperative stage, immobilization of the arm and hand is usually provided by well-padded plaster casts, splints, or braces. The period of immobilization is dependent on the surgical techniques performed. In general this is 3 to 4 weeks to allow for tendon healing<sup>41</sup>; however, some centers commence mobilization exercises within days of surgery.<sup>28</sup> With regard to rehabilitation after tendon transfer surgery, published literature refers to triggering the transferred muscles to be active in its original role, use of electrical stimulation or biofeedback as required, and instructions to use the transferred muscle as much as possible.<sup>12,49-52</sup> Although the techniques used are dependent on the procedures performed, in general current practice consists of regaining active and passive range of motion after immobilization, reeducation of new muscle action, and then learning/practice of functional tasks and ADL. This relearning process is time-consuming and demanding and not only involves specific skills training but also training in self-efficacy, self-belief, and confidence building. This then enables the person with tetraplegia to translate the new skills from surgery into all life domains.<sup>53,54</sup> The improvements in function after tendon transfer surgery have been shown to continue for up to 12 months postsurgery,<sup>55</sup> and effects of this improvement in function continue for an individual's lifetime.<sup>54</sup>

## Outcomes after tendon transfer surgery

A number of studies have explored the outcomes of tendon transfer surgery for people with tetraplegia. Evidence of the

**Table 1** Common surgical procedures

ISNCSCI	ICSHT	Desired Function	Possible Reconstructive Procedures
C5	0	No muscles available for transfer	
		Elbow extension	PD to triceps or biceps to triceps
	1	Wrist extension	BR to ECRB
		Key pinch	FPL tenodesis Split distal FPL tenodesis
C6	1-3	Elbow extension	PD to triceps or biceps to triceps
		Key pinch	BR to FPL or FPL tenodesis Split distal FPL tenodesis
		Thumb extension	EPL tenodesis
		Gross grasp	BR to FDP or ECRL to FDP
		Gross release	EDC tenodesis
C7*	4-7	Key pinch	BR to FPL or PT to FPL Split distal FPL tenodesis
		Gross grasp	ECRL to FDP or PT to FDP
		Gross release	PT to EDC
C8	8 and 9	Thumb opposition	ECU to FCU to FPL using FDS

Abbreviations: BR, brachioradialis; ECRB, extensor carpi radialis brevis; ECRL, extensor carpi radialis longus; ECU, extensor carpi ulnaris; EDC, extensor digitorum communis; EPL, extensor pollicis longus; FCU, flexor carpi ulnaris; FDS, flexor digitorum superficialis; FPL, flexor pollicis longus; ICSHT, International Classification for Surgery of the Hand in Tetraplegia; PD, posterior deltoid; PT, pronator teres.

\* There are many surgical options for ICSHT classes 4 through 7, and depending on surgeons' choice a number of different motors may be transferred to provide the function required.

functional gains from these procedures that have been summarized in 3 comprehensive systematic reviews of the literature.<sup>27,56,57</sup> However, all 3 reviews commented on the lack of high-quality studies because of the variability of SCI levels, leading to small sample sizes compounded by the numerous surgical approaches and use of different assessment tools for evaluation.

## Elbow extension surgery

In a systematic review of the literature, Hamou et al<sup>56</sup> found that mean elbow extension strength after deltoid-triceps transfers improved from preoperatively Medical Research Council grade 0 to grade 3 (out of 5) postoperatively. Provision of elbow extension stabilizes the elbow and provides greater range of movement in the horizontal plane. The ability to extend the hand in space by an additional 30cm results in an additional 800% of space that the hand can reach.<sup>58</sup> Measurement of self-identified goals after deltoid-triceps surgery demonstrated clinically important improvements and high satisfaction of the performance of the goal.<sup>59</sup> Unsurprisingly, commonly identified goals after deltoid-triceps surgery are within the mobility domain of the ICF, which include propelling a wheelchair and transfers.<sup>55,59,60</sup> Goals directly related to self-care and dressing, driving a vehicle, and positioning arms when lying down have demonstrated the greatest level of satisfaction after surgery.<sup>59</sup> A smaller number of studies have reported outcomes after biceps-triceps surgery with similar improvements in elbow extension ability noted.<sup>51-53,61</sup>



## Pinch and grip reconstruction surgery

Impairment-level gains in pinch and grip strength after tendon transfers are small but important for individuals in terms of improvements in arm/hand function. From a systematic review of published literature, the mean postoperative pinch strength has been synthesized to be 2kg, where previously it was 0.<sup>56</sup> Improvement in pinch and grip strength improves an individual's ability to perform ADL without the need for orthoses or adaptive equipment.<sup>51,62</sup> This includes tasks such as feeding, drinking, and self-care.<sup>6,63</sup> In addition, many tasks that were impossible to perform prior to surgery are able to be performed after surgery.<sup>17,55,64,65</sup> Improvements in independence in all aspects of daily living have been reported after pinch and grip reconstruction surgery that then gives confidence in other areas of life.<sup>39,54,66</sup> In a longitudinal study on tendon transfer surgery, strength of tendon transfers have been maintained for up to 20 years after surgery, to date.<sup>67</sup> Patient satisfaction after upper limb reconstructive surgery is high.<sup>39,55,62,63,68</sup>

## Conclusions

This article has provided an overview of tendon transfers for restoration of upper limb in people with tetraplegia. Comprehensive multidisciplinary assessment of the individual before and after surgery is important to create the surgical plan and rehabilitation goals and establish and measure level of functioning. Improvements in strength and performance of ADL tasks after surgery frequently translate into improvements in self-confidence and independence in other life domains. Outcomes of these surgical techniques can take up to 12 months and beyond after surgery to be fully realized.

## Keywords

Quadriplegia; Reconstructive surgical procedures; Rehabilitation; Tendon transfer; Upper extremity

## Corresponding author

Jennifer A. Dunn, PhD, Physiotherapy Department, Burwood Hospital, Private Bag 4708, Christchurch, New Zealand 8140.  
E-mail address: [jennifer.dunn@otago.ac.nz](mailto:jennifer.dunn@otago.ac.nz).

## References

- Hanson RW, Franklin MR. Sexual loss in relation to other functional losses for spinal cord injured males. *Arch Phys Med Rehabil* 1976; 57:291-3.
- Anderson KD. Targeting recovery: priorities of the spinal cord-injured population. *J Neurotrauma* 2004;21:1371-83.
- Bryden AM, Sinnott KA, Mulcahey MJ. Innovative strategies for improving upper extremity function in persons with tetraplegia and considerations in measuring functional outcomes. *Top Spinal Cord Inj Rehabil* 2005;10:75-93.
- DiPasquale-Lehnerz P. Orthotic intervention for development of hand function with C-6 quadriplegia. *Am J Occup Ther* 1994;48:138-44.
- Krajnik SR, Bridle MJ. Hand splinting in quadriplegia: current practice. *Am J Occup Ther* 1992;46:149-56.
- Mohammed KD, Rothwell AG, Sinclair SW, Willems SM, Bean AR. Upper limb surgery in tetraplegia. *J Hand Surg [Br]* 1992;74:873-9.
- Lamb DW, Chan KM. Surgical reconstruction of the upper limb in traumatic tetraplegia. *J Hand Surg [Br]* 1983;65:291-8.
- Freehafer AA. Tendon transfers in patients with cervical spinal cord injury. *J Hand Surg [Am]* 1991;16:804-9.
- Ejeskar A, Dahllof A. Results of reconstructive surgery in the upper limb of tetraplegia patients. *Paraplegia* 1988;26:204-8.
- McDowell CL, Moberg E, House JH. The Second International Conference on Surgical Rehabilitation of the Upper Limb in Tetraplegia (quadriplegia). *J Hand Surg [Am]* 1986;11:604-8.
- Hentz VR, Brown M, Keoshian LA. Upper limb reconstruction in quadriplegia: functional assessment and proposed treatment modifications. *J Hand Surg [Am]* 1983;8:119-31.
- Gansel J, Waters RL, Gellman H. Transfer of the pronator teres tendon to the tendons of the flexor digitorum profundus in tetraplegia. *J Hand Surg [Am]* 1990;72:427-32.
- Keith MW, Lacey SH. Surgical rehabilitation of the tetraplegic upper extremity. *Neurorehabil Neural Repair* 1991;5:75-87.
- Moberg E. Surgical treatment for absent single-hand grip and elbow extension in quadriplegia. Principles and preliminary experience. *J Hand Surg [Am]* 1975;57:196-206.
- Ejeskär A. Upper limb surgical rehabilitation in high-level tetraplegia. *Hand Clin* 1988;4:585-99.
- Johanson ME, Murray WM. The unoperated hand: the role of passive forces in hand function after tetraplegia. *Hand Clin* 2002;18:391-8.
- Smaby N, Johanson E, Baker B, Kenney DE, Murray WM, Hentz VR. Identification of key pinch forces required to complete functional tasks. *J Rehabil Res Dev* 2004;41:215-24.
- Freehafer AA, Peckham PH, Keith MW. New concepts on treatment of the upper limb in the tetraplegic: surgical restoration and functional neuromuscular stimulation. *Hand Clin* 1988;4:563-74.
- van Zyl N, Hahn JB, Cooper CA, Weymouth MD, Flood SJ, Galea MP. Upper limb reinnervation in C6 tetraplegia using a triple nerve transfer: case report. *J Hand Surg [Am]* 2014;39:1779-83.
- Bertelli JA, Tacca CP, Ghizoni MF, Kechele PR, Santos MA. Transfer of supinator motor branches to the posterior interosseous nerve to reconstruct thumb and finger extension in tetraplegia: case report. *J Hand Surg [Am]* 2010;35:1647-51.
- Friden J, Gohritz A. Brachialis-to-extensor carpi radialis longus selective nerve transfer to restore wrist extension in tetraplegia: a case study. *J Hand Surg [Am]* 2012;37:1606-8.
- Brown JM. Nerve transfers in tetraplegia I: Background and technique. *Surg Neurol Int* 2011;2:121.
- Burns AS, Ditunno JF. Establishing prognosis and maximizing functional outcomes after spinal cord injury: a review of current and future directions in rehabilitation management. *Spine (Phila Pa 1976)* 2001;26(24 Suppl):S137-45.
- Waters RL, Adkins RH, Yakura JS, Sie IH. Motor and sensory recovery following complete tetraplegia. *Arch Phys Med Rehabil* 1993; 74:242-7.
- Waters RL, Sie IH, Gellman H, Tognella M. Functional hand surgery following tetraplegia. *Arch Phys Med Rehabil* 1996;77:86-94.
- McDowell CL, House JH. Tetraplegia. In: Green DP, Hotchkiss RN, Pederson WC, editors. *Green's operative hand surgery*. 4th ed. Philadelphia: Churchill Livingstone; 1999. p 1597-617.
- Connolly SJ, Aubut JL, Teasell R, Jarus T; SCIRE Research Team. Enhancing upper extremity function with reconstructive surgery in persons with tetraplegia: a review of the literature. *Top Spinal Cord Inj Rehabil* 2007;13:58-80.
- Friden J, Reinholdt C, Turcsanyii I, Gohritz A. A single stage operation for reconstruction of hand flexion, extension and intrinsic function in tetraplegia: the alphabet procedure. *Tech Hand Up Extrem Surg* 2011;15:230-5.
- Wolfe SW, Hotchkiss RN, Pederson WC, Kozin SH. Tetraplegia. In: Wolfe SW, editor. *Green's operative hand surgery*. 6th ed. Philadelphia: Churchill Livingstone; 2011. p 1122-45.
- Freehafer AA, Kelly CM, Peckham PH. Tendon transfer for the restoration of upper limb function after a cervical spinal cord injury. *J Hand Surg [Am]* 1984;9:887-93.

31. Johanson ME, Murray WM, Hentz VR. Comparison of wrist and elbow stabilization following pinch reconstruction in tetraplegia. *J Hand Surg [Am]* 2011;36:480-5.
32. Rothwell A, Sinnott KA, Mohammed KD, Dunn JA, Sinclair SW. Upper limb surgery for tetraplegia: a 10-year re-review of hand function. *J Hand Surg [Am]* 2003;28:489-97.
33. Freehafer AA. Gaining independence in tetraplegia. *Clin Orthop Relat Res* 1998;355:282-9.
34. House JH, Shannon MA. Restoration of strong grasp and lateral pinch in tetraplegia: a comparison of two methods of thumb control in each patient. *J Hand Surg [Am]* 1985;10:21-9.
35. Kirshblum SC, Burns SP, Biering-Sorensen F, et al. International standards for neurological classification of spinal cord injury (revised 2011). *J Spinal Cord Med* 2011;34:535-46.
36. Mulcahey MJ, Hutchinson D, Kozin SH. Assessment of the upper limb in tetraplegia: considerations in evaluation and outcomes research. *J Rehabil Res Dev* 2007;44:91-102.
37. World Health Organization. *International Classification of Functioning, Disability and Health*. Geneva: World Health Organization; 2002.
38. Dunn JA, Sinnott KA, Bryden AM, Connolly SJ, Rothwell AG. Measurement issues related to upper limb interventions in persons who have tetraplegia. *Hand Clin* 2008;24:161-8.
39. Sinnott KA, Dunn JA, Rothwell AG. Use of the ICF conceptual framework to interpret hand function outcomes following tendon transfer surgery for tetraplegia. *Spinal Cord* 2004;42:369-400.
40. Sinnott KA, Dunn JA, Rothwell AG, Hall A, Post MW. The development of the NZ based International Upper Limb Surgery Registry. *Spinal Cord* 2014;52:611-5.
41. Revol M, Cormerais A, Laffont I, Pedelucq JP, Dizien O, Servant JM. Tendon transfers as applied to tetraplegia. *Hand Clin* 2002;18:423-39.
42. House J, McCarthy C. *Intrinsic balancing in reconstruction of the tetraplegic hand. Current trends in hand surgery*. Amsterdam: Elsevier Science; 1995.
43. McCarthy CK, House JH, Heest AV, Kawiecki JA, Dahl A, Hanson D. Intrinsic balancing in reconstruction of the tetraplegic hand. *J Hand Surg [Am]* 1997;22:596-604.
44. Leclercq C. Surgical rehabilitation for the weaker patients (groups 1 and 2 of the International Classification). *Hand Clin* 2002;18:461-79.
45. Kozin SH, D'Addesi L, Chafetz RS, Ashworth S, Mulcahey M. Biceps-to-triceps transfer for elbow extension in persons with tetraplegia. *J Hand Surg [Am]* 2010;35:968-75.
46. Endress RD, Hentz VR. Biceps-to-triceps transfer technique. *J Hand Surg [Am]* 2011;36:716-21.
47. Dunkerley AL, Ashburn A, Stack EL. Deltoid triceps transfer and functional independence of people with tetraplegia. *Spinal Cord* 2000;38:435-41.
48. Netscher DT, Sandvall BK. Surgical technique: posterior deltoid-to-triceps transfer in tetraplegic patients. *J Hand Surg [Am]* 2011;36:711-5.
49. Vanden Berghe A, Van Laere M, Hellings S, Vercauteren M. Reconstruction of the upper extremity in tetraplegia: functional assessment, surgical procedures and rehabilitation. *Paraplegia* 1991;29:103-12.
50. Lo IK, Turner R, Connelly S, Delaney G, Roth JH. The outcome of tendon transfers for C6-spared quadriplegics. *J Hand Surg [Br]* 1998;23:156-61.
51. Johnson DL, Gellman H, Waters RL, Tognella M. Brachioradialis transfer for wrist extension in tetraplegic patients who have fifth-cervical-level neurological function. *J Hand Surg [Am]* 1996;78:1063-7.
52. Forner-Cordero I, Mudarra-Garcia J, Forner-Valero JV, Vilar-de-la-Pena R. The role of upper limb surgery in tetraplegia. *Spinal Cord* 2003;41:90-6.
53. Wangdell J, Carlsson G, Friden J. From regained function to daily use: experiences of surgical reconstruction of grip in people with tetraplegia. *Disabil Rehabil* 2014;36:678-84.
54. Sinnott KA, Brander P, Siegart RJ, Rothwell AG, De Jong G. Life impacts following reconstructive hand surgery for tetraplegia. *Top Spinal Cord Inj Rehabil* 2009;15:90-7.
55. Wangdell J, Friden J. Satisfaction and performance in patient selected goals after grip reconstruction in tetraplegia. *J Hand Surg Eur Vol* 2010;35:563-8.
56. Hamou C, Shah NR, DiPonio L, Curtin CM. Pinch and elbow extension restoration in people with tetraplegia: a systematic review of the literature. *J Hand Surg [Am]* 2009;34:692-9.
57. Kalsi-Ryan S, Verrier MC. A synthesis of best evidence for the restoration of upper-extremity function in people with tetraplegia. *Physiother Can* 2011;63:474-89.
58. Hentz VR, Leclercq C. *Surgical rehabilitation of the upper limb in tetraplegia*. New York: WB Saunders; 2002.
59. Wangdell J, Friden J. Activity gains after reconstruction of elbow extension in patients with tetraplegia. *J Hand Surg [Am]* 2012;37:1003-10.
60. Lamberg AS, Fridén J. Changes in skills required for using a manual wheelchair after reconstructive hand surgery in tetraplegia. *J Rehabil Med* 2011;43:714-9.
61. Mulcahey MJ, Lutz C, Kozin SH, Betz RR. Prospective evaluation of biceps to triceps and deltoid to triceps for elbow extension in tetraplegia. *J Hand Surg [Am]* 2003;28:964-71.
62. Meiners T, Abel R, Lindel K, Mesecke U. Improvements in activities of daily living following functional hand surgery for treatment of lesions to the cervical spinal cord: self-assessment by patients. *Spinal Cord* 2002;40:574-80.
63. Woulle KS, Bryden AM, Peckham PH, Murray PK, Keith M. Satisfaction with upper-extremity surgery in individuals with tetraplegia. *Arch Phys Med Rehabil* 2003;84:1145-9.
64. Mulcahey MJ, Betz RR, Smith BT, Weiss AA. A prospective evaluation of upper extremity tendon transfers in children with cervical spinal cord injury. *J Pediatr Orthop* 1999;19:319-28.
65. Waters RL, Moore KR, Graboff SR, Paris K. Brachioradialis to flexor pollicis longus tendon transfer for active lateral pinch in the tetraplegic. *J Hand Surg [Am]* 1985;10A:385-91.
66. Wangdell J, Carlsson G, Fridén J. Enhanced independence: experiences after regaining grip function in people with tetraplegia. *Disabil Rehabil* 2013;35:1968-74.
67. Dunn JA, Rothwell AG, Mohammed KD, Sinnott KA. The effects of aging on upper limb tendon transfers in patients with tetraplegia. *J Hand Surg [Am]* 2014;39:317-23.
68. Focks-Feenstra JJ, Snoek G, Bongers-Janssen H, Nene A. Long-term patient satisfaction after reconstructive upper extremity surgery to improve arm—hand function in tetraplegia. *Spinal Cord* 2011;49:903-8.